

MALIGNANCY RISK AND FALSE NEGATIVE RATE OF FINE NEEDLE ASPIRATION CYTOLOGY IN THYROID NODULES EQUAL OR GREATER THAN 4 CM

Nagihan BESTEPE¹, Didem OZDEMİR¹, Abbas Ali TAM¹, Fatma Dilek DELLAL¹, Aydan KILICASLAN², Omer PARLAK³, Reyhan ERSOY¹, Bekir ÇAKIR¹

¹ Yildirim Beyazıt University, School of Medicine, Department of Endocrinology and Metabolism, Ankara, Turkey

² Yildirim Beyazıt University, School of Medicine, Department of Pathology, Ankara, Turkey

³ Yildirim Beyazıt University, School of Medicine, Department of General Surgery, Ankara, Turkey

Introduction

➤ We aimed to evaluate malignancy rate in thyroid nodules ≥ 4 cm and determine false negativity of fine needle aspiration biopsy (FNAB) in these nodules.

Methods

➤ Patients who underwent thyroidectomy between January 2007 and December 2014 in our institution were reviewed. Demographical and clinical data and preoperative ultrasonography (US) findings were obtained from the medical records. The nodules in these patients were grouped as ≥ 4 cm and < 4 cm according to US measurements. Nodules < 4 cm were further divided into 1-3.9 cm and < 1 cm. US features and malignancy rates were compared. Histopathologically malignant nodules with preoperative benign cytology were defined to have false negative FNAB.

Results

➤ Data of 5561 nodules in 2463 patients were analyzed. There were 1008 nodules ≥ 4 cm, 4013 nodules 1-3.9 cm and 540 nodules < 1 cm. Histopathologically, 8.5%, 10.2% and 25.6% of nodules ≥ 4 cm, 1-3.9 cm and < 1 cm were malignant, respectively ($p < 0.001$). There was no significant difference between the 1-3.9 cm and ≥ 4 cm nodules with respect to malignancy ($p = 0.108$) (Figure 1). Preoperative US features were similar in histopathologically benign and malignant nodules ≥ 4 cm, except higher prevalence of hypoechoic appearance in malignant ones ($p = 0.02$). False negativity rates were 4.7% (32/683) in ≥ 4 cm, 2.2% (45/2093) in 1-3.9 cm and 4.8% (10/206) in < 1 cm nodules. < 1 cm and ≥ 4 cm nodules had similar false negativity ($p = 0.93$), while 1-3.9 cm nodules had statistically lower false negativity than both groups ($p = 0.03$ and $p < 0.001$, respectively) (Figure 2).

Figure 1: Final histopathological results of all thyroid nodules according to size

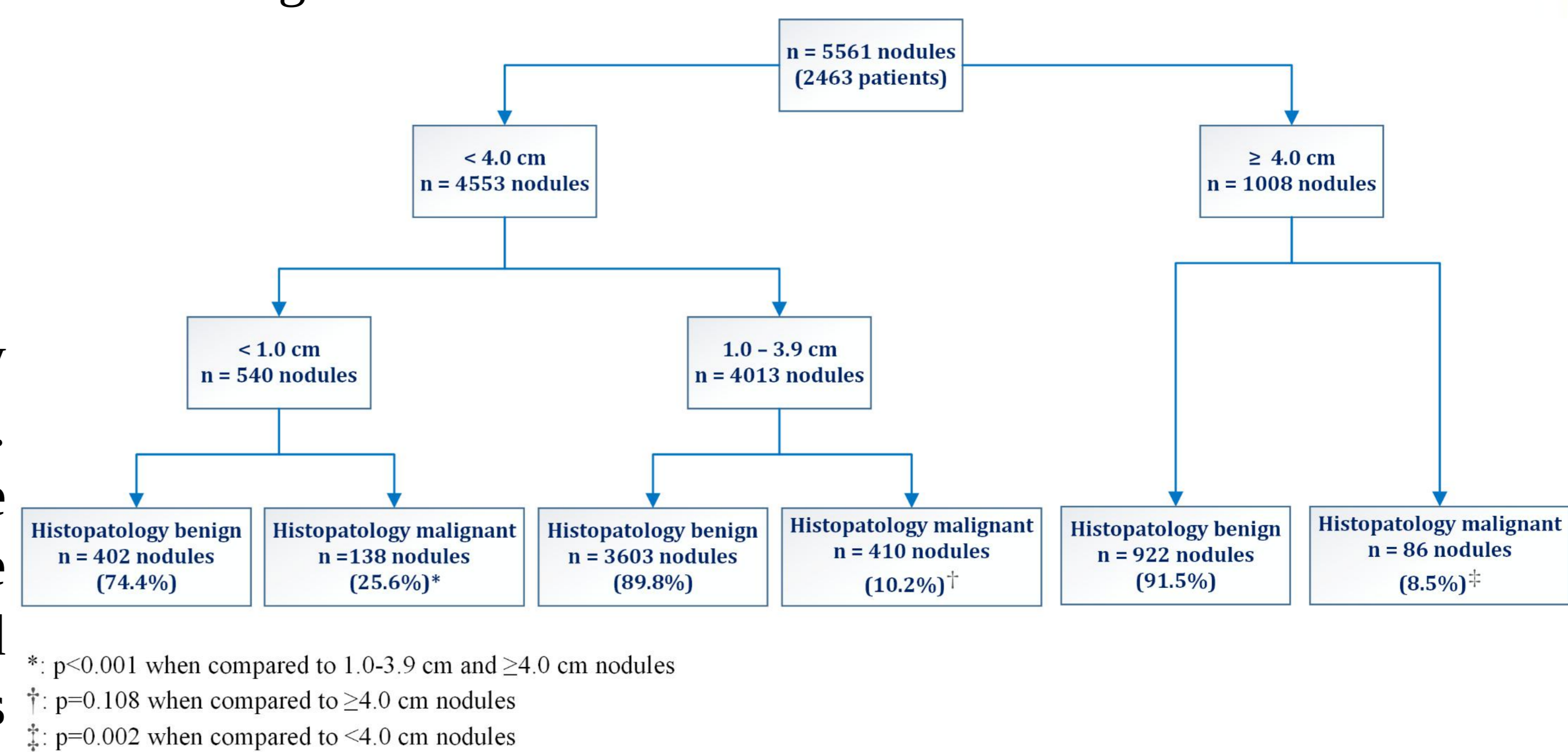
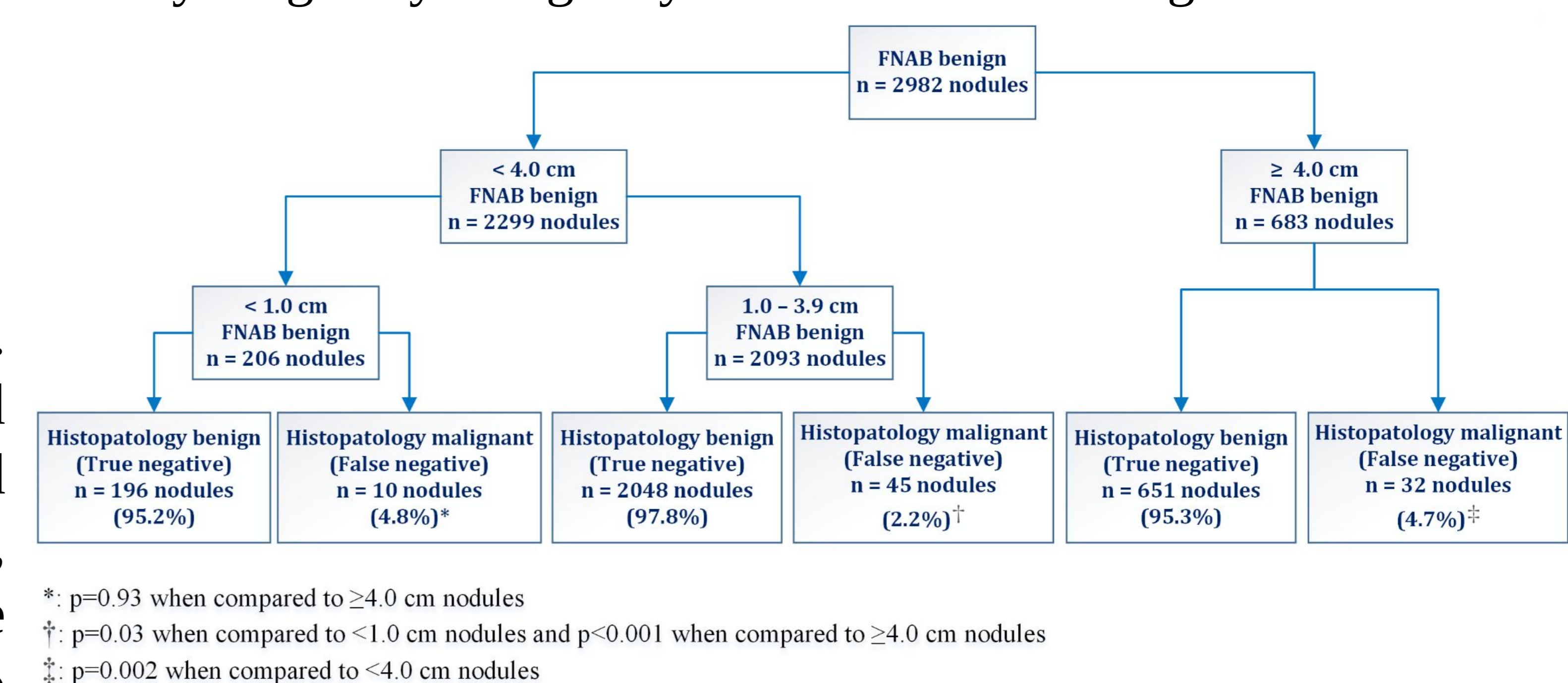


Figure 2: Final histopathological results and false negative rates of cytologically benign thyroid nodules according to size



Conclusion

➤ Malignancy rate in thyroid nodules ≥ 4 cm is similar with nodules 1-3.9 cm. Although false negativity of FNAB was significantly higher in ≥ 4 cm than 1-3.9 cm nodules, the rate was 4.7% which we think not high enough to recommend routine surgery when cytology was benign.